



# Immune reconstitution syndrome associated with opportunistic mycoses



Nina Singh, John R Perfect

Host immunity is essential in facilitating the eradication of infection. However, immunological recovery and an imbalance characterised by either suboptimum or excessive expression of immune responses can also be harmful to the host. Inflammatory responses triggered by rapid resolution of immunosuppression can lead to a series of localised and systemic reactions, termed immune reconstitution syndrome (IRS), that are often misconstrued as failure of specific antifungal therapy to eliminate the offending fungal pathogen. Recognition of IRS has become increasingly relevant in the context of our current use of potent immunosuppressive agents and immunostimulators that allow rapid manipulation of the immune system. Whereas the conceptual principles of IRS underscore the adverse effects of an overzealous and dysregulated immune response, they also support a role of immunotherapies to augment immunity if induction of endogenous responses is inadequate for the control of infection.

## Introduction

In the era of improved antifungal drugs and the frequent use of immunomodulators with both immunostimulatory and immunosuppressive capabilities, clinicians have reached an important therapeutic crossroads. As Casadevall and Pirofski<sup>1</sup> have elegantly outlined, the primary focus of a fungus–host interaction is a disease that arises from both the invading organism and host immunity. A major determinant of outcome after fungal infection is the characteristics of the host immune response, which may range from suboptimum or ineffective to excessive and inappropriate.<sup>1</sup> Ideally, the host achieves the so-called Goldilocks paradigm, whereby the immune response is neither too much nor too little, and just right; however, this rarely happens efficiently except in normal hosts.

All too often in the treatment of fungal infections, therapeutic failure is identified as our inability to kill the invading yeasts or moulds. Our therapeutic focus has been on providing as rapid and as effective an immune reconstitution as possible in immunosuppressed patients with refractory fungal infections.<sup>2</sup> However, what is not fully appreciated is that although host immunity is crucial in the eradication of infection, immunological recovery can also be detrimental and may contribute towards worsening disease expression. For instance, soon after the advent of potent antiretroviral therapy, successful immune restoration in HIV-infected patients became associated with an exuberant inflammatory response and worsening clinical manifestations of opportunistic infections.<sup>3–6</sup> This entity, known as immune reconstitution syndrome (IRS), is also seen in other immunocompromised hosts, and even in immunocompetent individuals.<sup>7–9</sup> IRS is best characterised as a collection of localised and systemic inflammatory reactions of varying degrees that have both beneficial and noxious features during an invasive mycosis.

However, the concept of IRS and its precise diagnosis in the context of opportunistic mycoses remains poorly

characterised for health-care providers. Occurrence of IRS is almost always construed as failure of therapy or a relapse caused by inability to eliminate the fungus, often leading to unwarranted or inappropriate changes in specific antifungal treatment.<sup>7,10,11</sup> Accordingly, its management is driven by sophisticated image studies and non-specific clinical signs and symptoms of inflammation rather than precise gauging of immunological recovery. Development of IRS also contributes to increased health-care costs and resource use.<sup>12</sup> In this Review, we discuss the current state of knowledge about the pathophysiological basis, clinical characteristics, and approach to the management of opportunistic mycoses-associated IRS.

## Pathophysiological basis of IRS

### Host immune responses

The conceptual paradigm underlying IRS is clinically detectable immune reconstitution in an immunosuppressed host—for instance, enhanced immune responsiveness resulting from initiation of antiretroviral therapy in HIV-infected patients or from reduction of immunosuppression in transplant recipients. The available evidence suggests that reconstitution of pathogen-specific immunity and an inflammatory response triggered by resolving immunosuppression is the most likely basis for IRS (figure).

Cytokine-secreting effector T cells play a major part in mediating immune responses to self and foreign antigens.<sup>13</sup> Activation by cognate ligand causes precursor CD4 lymphocytes (T-helper 0 [Th0] cells) to differentiate into cells with distinctive cytokine responses. Th1 cells, characterised by the production of interferon  $\gamma$ , elicit proinflammatory responses.<sup>14</sup> Th2 cells produce anti-inflammatory and immunosuppressive cytokines (eg, interleukin 10).<sup>13,15</sup> The cells that secrete transforming growth factor  $\beta$  are termed Th3 cells.<sup>16,17</sup> These, in concert with Th2 cells, inhibit the development and function of Th1 cells. A normally functioning immune system is the result of fine balance between Th1 and Th2 or Th3 cells. An imbalance characterised by an inadequate or

*Lancet Infect Dis* 2007; 7: 395–401

Published Online

April 24, 2007

DOI: 10.1016/S1473-

3099(07)70085-3

Infectious Disease Section, VA Medical Center, University of Pittsburgh, Pittsburgh, PA, USA (N Singh MD); and Department of Medicine and Microbiology, Duke University, Durham, NC, USA (J R Perfect MD)

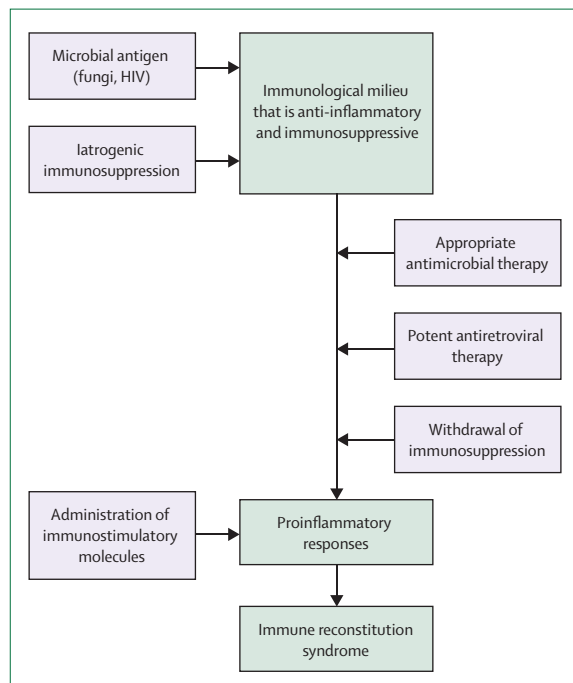
Correspondence to:

Dr Nina Singh, VA Medical Center, Infectious Disease Section, University Drive C, Pittsburgh, PA 15240, USA.

Tel +1 412 688 6179;

fax +1 412 688 6950;

nis5@pitt.edu



**Figure: Proposed pathological basis of IRS**

Microbial antigen and receipt of immunosuppressive agents lead to anti-inflammatory responses. Receipt of appropriate antimicrobial therapy, reduction of immunosuppression, or direct use of immune-stimulatory cytokines such as interferon  $\gamma$  and granulocyte colony-stimulating factor or granulocyte-macrophage colony-stimulating factor promote an inflammatory response that might lead to IRS.

excessive expression of either response can be detrimental to the infected host.

During retroviral infections, opportunistic infection-associated IRS is usually observed after initiation of antiretroviral therapy in naive HIV-infected patients.<sup>3,4,6</sup> HIV-RNA concentrations decline and recovery of immune effector cells ensues after the start of antiretroviral therapy.<sup>18</sup> Initial repopulation with CD45RO (memory T cells) is followed 4–6 weeks later by an increase in CD45RA and CD62L (naive CD4 cells) and a shift in T-cell receptor repertoire from Th2 to Th1.<sup>6,18–20</sup> Development of IRS has been proposed to occur at this stage of immunity, and this timing is consistent with the usual clinical occurrence of IRS within 2 months of initiation of antiretroviral therapy.<sup>21</sup>

Th1 cytokines are also the primary mediators of allograft rejection and are the main targets of immunosuppressive agents in transplant recipients.<sup>22,23</sup> In patients receiving calcineurin inhibitors, the concentrations of interleukin 10 compared with Th1 cytokines were raised.<sup>24</sup> Intra-graft mRNA expression of interferon  $\gamma$  and interleukin 12 was also inhibited by tacrolimus.<sup>25</sup> In fact, suppression of interferon  $\gamma$  was greater with tacrolimus than with ciclosporin A.<sup>24</sup> Mycophenolate mofetil inhibits de-novo purine synthesis and impairs T-cell immunity.<sup>26</sup> Alemtuzumab, a CD52 antibody, provides prolonged

suppression of CD4 cells, and tolerance to foreign antigens and microbial invaders. Corticosteroids, although less potent inhibitors of Th1 than calcineurin inhibitors, are also associated with a decrease in inflammatory responses.<sup>27,28</sup> Thus, iatrogenic immunosuppression in transplant recipients is associated with a dominant anti-inflammatory response. Reduction or withdrawal of these potent immunosuppressive agents can rapidly lead to a shift towards a proinflammatory phenotype, particularly if an invading pathogen is established in host tissue during immune suppression. With the ability to rapidly control bone-marrow production of progenitor cells, the pronounced swings in host cells from profound neutropenia to leucocytosis with chemotherapy and cytokines, a fungus could establish itself in tissues to rapidly become an inciting agent for a host inflammatory storm.

#### Pathogen-mediated immunosuppression

Offending pathogens may also contribute to a state of immunosuppression that is then potentially reversible on initiation of antifungal therapy. Experimental studies have shown that *Cryptococcus neoformans* has immunomodulatory characteristics and preferentially inhibits Th1 while inducing Th2 responses.<sup>15,29,30</sup> The exact relevance of these data in vitro and in animals for human disease is incompletely discerned. Nevertheless, several reports have shown that patients with cryptococcal meningitis have defective production of interferon  $\gamma$  and tumour necrosis factor  $\alpha$ ,<sup>31</sup> with or without high interleukin-10 concentrations in the cerebrospinal fluid.<sup>32–34</sup> Furthermore, higher interferon- $\gamma$  concentrations in the cerebrospinal fluid correlated with an improved clinical response during treatment of CNS cryptococcosis.<sup>35</sup> However, the receipt of antifungal therapy in a patient with *Cryptococcus gattii* meningitis was associated with a pronounced reversion of Th2 to Th1 response with an exacerbation of clinical inflammatory manifestations, although the yeast was ultimately eradicated from the site.<sup>9</sup>

In addition to antigen-specific responses, *C. neoformans* is capable of eliciting an innate T-lymphocyte response as a mitogen.<sup>36</sup> Mitogen-activated T cells could potentially lead to potent proinflammatory responses and therefore IRS. Even specific antibody responses to the invading fungus may contribute to inflammatory imbalance during immune reconstitution. A phenomenon, similar to a prozone-like effect, whereby too much antibody enhances disease, has been described in cryptococcosis.<sup>37,38</sup> In fact, in experimental cryptococcosis, antibody-mediated immunity may be protective, non-protective, or even harmful to the host, depending on its concentration relative to the inoculum of *C. neoformans*.<sup>38</sup> For instance, concentrations of IgM and IgG antibodies specific to glucuronoxylomannan, a component of the cryptococcal polysaccharide capsule, were higher in transplant recipients who developed cryptococcosis than in those

who did not.<sup>39</sup> The precise contribution of this immunoglobulin dysregulation to IRS remains to be elucidated, but it shows the potential ability of the fungus to directly drive an inappropriate immune response.

### Epidemiological characteristics and risk factors HIV infection

Although IRS has been reported with *Histoplasma capsulatum*,<sup>40</sup> *Pneumocystis jirovecii*,<sup>41</sup> and aspergillus infections,<sup>42</sup> the syndrome is best characterised in context of *C neoformans* infection. IRS was reported in 30–33% of HIV-infected patients with *C neoformans* after the initiation of antiretroviral therapy.<sup>43,44</sup> Lower CD4-cell count and higher HIV-RNA concentrations at the onset of infection correlated with a higher risk of IRS.<sup>43</sup> Patients with IRS also had a greater reduction in HIV-RNA concentration within 90 days of antiretroviral therapy initiation,<sup>12</sup> and had a greater fungal burden at the onset of infection.<sup>43,44</sup> Furthermore, initiation of antiretroviral therapy within 30–60 days of the treatment of fungal infection has been associated with a higher risk of IRS.<sup>12,21,43</sup>

### Transplantation

IRS was observed in 5% of the solid-organ transplant recipients, a median of 5.5 weeks after the start of antifungal therapy.<sup>7</sup> Transplant recipients with IRS were more likely to have received a potent immunosuppressive regimen than those without IRS. After reduction of immunosuppressive therapy, a relative increase in Th1 response may have been greater in patients receiving more potent immunosuppression and therefore a higher risk for the occurrence of IRS.

### Pregnancy

An immunosuppressive status characterised by anti-inflammatory responses is crucial for maintaining pregnancy. This is largely established by the expression of interleukin 10 and transforming growth factor  $\beta$  by maternal tissue and simultaneous inhibition of Th1 cytokines.<sup>45,46</sup> Rapid reversal of this immunological repertoire in the postpartum period can lead to severe complications caused by IRS with mycoses.<sup>9</sup> For instance, before the advent of specific therapy, a woman who tolerated chronic cryptococcal meningitis for more than 15 years deteriorated after her second pregnancy and died.<sup>46</sup> Another woman developed IRS with induction of a vigorous Th1 response after delivery of a baby and treatment for cryptococcal meningitis.<sup>9</sup>

### Neutropenia

In neutropenic patients with pulmonary aspergillosis, the risk of life-threatening pulmonary complications substantially increased when the neutrophil counts rose rapidly from severe neutropenia to greater than 4500 per  $\mu\text{L}$  within 5 days of receiving colony-stimulating growth factor compared with patients with a more gradual

recovery from neutropenia.<sup>47</sup> There are many reports of respiratory failure or worsening radiographs in patients with invasive pulmonary aspergillosis as rapid neutrophil recovery occurs.<sup>48,49</sup> In fact, despite the widespread use of colony-stimulating factors and their ability to reduce the duration of neutropenia, a definitive benefit of these immunomodulators in the treatment of invasive aspergillosis has not yet been shown,<sup>50</sup> a finding that may be related to imprecise control of inflammatory responses.

### Other risk factors

A genetic predisposition to IRS has been suggested in patients with IRS associated with cytomegalovirus and mycobacterial infections.<sup>51,52</sup> Therefore, robust studies are needed to validate and define potential genetic susceptibility to IRS during mycoses. Furthermore, specific characteristics of the fungus or strain variations might have a contributory role in IRS. For example, *C gattii* seems to cause a substantial chronic inflammatory reaction at the site of infection that is consistently more prominent than with *C neoformans*.<sup>53</sup> This may be because of intrinsic differences in the characteristics of the yeast species or simply because *C gattii* preferentially infects more immunocompetent individuals.

### Clinical manifestations

*C neoformans*-associated IRS typically presents as lymphadenitis, enhancing CNS lesions, or skin or soft-tissue lesions.<sup>43,44</sup> Increased intracranial pressure in association with aseptic meningitis and inflammatory lesions within the spinal cord have also been reported.<sup>54,55</sup> A hallmark of IRS lesions is granulomatous changes of which Th1 cells are the key initial mediators.<sup>56,57</sup> Granulomas are strongly associated with containment and resolution of infection.<sup>58</sup> In a renal-transplant recipient, administration of interferon  $\gamma$  was associated with the appearance of large granulomas at the site of cryptococcal cellulitis that heralded the resolution of an otherwise refractory infection.<sup>59</sup> Granulomas in IRS, particularly in the lymph nodes, may undergo necrosis and manifest as suppurative lesions. Cryptococci may be visualised histopathologically; however, cultures have been consistently negative for the organism.<sup>3,56,60</sup>

Renal-transplant recipients with cryptococcosis may experience allograft loss temporally related to the onset of IRS. In one study, the overall probability of allograft survival after *C neoformans* infection was significantly lower in patients who developed IRS than in those who did not ( $p=0.0004$ ).<sup>61</sup> The Th1 inflammatory response at the onset of IRS might have contributed to graft loss by upregulation of tissue rejection.<sup>61</sup>

IRS in histoplasmosis usually presents as focal or pronounced lymphadenitis that causes obstructive or compressive lesions.<sup>62,63</sup> Inflammatory CNS masses, soft-tissue or osteoarticular lesions, and uveitis have also been reported.<sup>4,62</sup> Unlike histiocytic infiltrates, typically

observed at the onset of infection, IRS-associated lymphadenitis was characterised by well-formed epithelioid and giant-cell granulomas.<sup>62</sup> Up to 5% of the cases of *P jirovecii* pneumonia have been shown to develop recurrent symptomatic disease 5–17 days after the start of antiretroviral therapy or discontinuation of adjunctive corticosteroids for the initial episode of pneumocystosis.<sup>41,64</sup> Patients with recurrence were more symptomatic and often developed acute respiratory failure.<sup>41,64</sup> Additionally, well before the recognition of *P jirovecii* in HIV-infected patients, 73% of the episodes of pneumocystosis in children with acute lymphocytic leukaemia occurred during remission (ie, recovery from neutropenia).<sup>65</sup>

Pulmonary infiltrates in patients with aspergillosis often show worsening during neutrophil recovery before improvement ensues on appropriate therapy.<sup>48</sup> The most common presentations of IRS in patients with aspergillus infections were recurrent clinical symptoms, and worsening pulmonary lesions radiographically.<sup>66</sup> Although it is difficult to ascertain whether these cases represented IRS with cell-mediated recovery or simply improvement in the numbers of inflammatory cells, histological findings in some patients can show granulomas consistent with IRS.<sup>66</sup>

A potentially helpful surrogate laboratory clue to IRS is hypercalcaemia after initiation of appropriate antimicrobial therapy.<sup>10,67</sup> Hypercalcaemia is a recognised response to granulomatous disorders,<sup>67,68</sup> with endogenous overproduction of 1,25-dihydroxyvitamin D by activated macrophages being the proposed mechanism.<sup>67,68</sup>

**Panel: Suggested diagnostic criteria for IRS associated with opportunistic mycoses\***

**All three criteria must be present for a positive diagnosis of IRS**

- New appearance or worsening of any of the following: clinical or radiographical manifestations consistent with an inflammatory process, such as contrast-enhancing lesions on neuroimaging studies (computed tomography or magnetic resonance imaging); cerebrospinal fluid pleocytosis (ie, >5 white blood cells per  $\mu\text{L}$ ); increased intracranial pressure (ie, opening pressure  $\geq 20$  mm H<sub>2</sub>O), with or without hydrocephalus; histopathology showing granulomatous lesions; unexplained hypercalcaemia.
- Symptoms occurring during receipt of appropriate antifungal therapy† that cannot be explained by a newly acquired infection.
- Negative results of cultures, or stable or reduced biomarkers for the initial fungal pathogen during the diagnostic work-up for the inflammatory process.

\*IRS is a collection of localised and systemic reactions of varying degrees with both positive and negative features, rather than a monolithic, rigidly definable entity.

†An attempt should be made to exclude intrinsic and de-novo drug resistance, and suboptimum drug concentrations, particularly in case of the newer azoles.

Hypercalcaemia was reported in one of four patients with IRS caused by cryptococcosis.<sup>10</sup>

## Management

The optimum management of IRS is dependent on the awareness by health-care providers of its existence. Recognition that IRS is a manifestation of a poorly-controlled inflammatory response rather than direct treatment failure of antifungal agents to eradicate or kill the fungus is crucial in avoiding unnecessary modifications in therapy. Currently, no readily available markers exist that can reliably establish the diagnosis of IRS. However, on the basis of published data,<sup>5,7,43</sup> the criteria outlined (panel) might be thought as representing IRS, and provide some reference in the discussion or study of this entity.

In therapy-naïve HIV-infected patients with opportunistic infections, consideration should be given to deferring the start of antiretroviral therapy for 4–10 weeks until the infection seems to be microbiologically controlled. This approach has been proposed for the treatment of *Mycobacterium tuberculosis* and *C neoformans* in these patients.<sup>12,44,69</sup> Similar rationale can also be applied to the management of immunosuppression in transplant recipients with these infections. Withdrawal of immunosuppression in transplant recipients with opportunistic infections is a common practice and is intuitively logical. However, concurrent withdrawal of immunosuppression and initiation of antifungal therapy has been shown to predispose not only to IRS, but also allograft loss.<sup>61</sup> Thus it is plausible that spacing or separating the reduction in post-transplant immunosuppression and initiation of antifungal therapy is a more prudent approach to the management of transplant recipients with cryptococcosis.<sup>61</sup>

We note that antifungal agents per se may have immunomodulatory effects. For example, amphotericin B deoxycholate promotes the transcription of pro-inflammatory cytokines.<sup>70</sup> The potential for induction of such responses is lower with the lipid formulations of amphotericin B.<sup>71</sup> Modification of Toll-like receptor signalling with liposomal amphotericin B was shown to induce an antifungal effect while attenuating the inflammatory cytotoxicity to the host.<sup>72</sup> Echinocandins, by modulating the amount of fungal  $\beta$ -glucan (that elicits proinflammatory responses), might also have indirect immunomodulatory effects.<sup>73</sup> The clinical relevance of these observations has yet to be fully discerned. IRS has also been reported in patients with opportunistic mycoses treated with the azoles, even though these drugs have little or no proinflammatory activity.<sup>10,62</sup>

There is no proven therapy for IRS. However, empirical treatment of symptomatic IRS in case reports or case series has been attempted using anti-inflammatory agents.<sup>3,21,40,60,66,74</sup> Existing data support the use of prednisone at 80 mg per day and tapered over 3 weeks in the management of severe *P jirovecii* pneumonia.<sup>75</sup>

A similar approach with longer tapering doses of corticosteroids has been used for the management of cryptococcosis-associated IRS.<sup>21,74</sup> On the basis of these preliminary data and until definitive studies are done, the use of tapering doses of corticosteroids over 6–8 weeks is a reasonable option in T-cell reconstitution-associated IRS that presents with severe organ dysfunction, other life-threatening conditions, or CNS manifestations. However, careful consideration and selection of the patients with cryptococcal meningitis who are to receive corticosteroids is important because glucocorticoid therapy has been associated with a poor outcome in a retrospective study.<sup>76</sup> We note, however, that in this study the use of corticosteroids was not based on clinical criteria and may simply have been a marker for patients with an extremely poor prognosis.

Although an overzealous or heightened inflammatory response may be life-threatening,<sup>77</sup> the inflammatory reaction in IRS is ultimately beneficial in eradicating the infection.<sup>9</sup> Induction of the endogenous immunological responses may be suboptimum for infection control, and augmentation of immune responses might be necessary for cure in severely immunosuppressed hosts. Indeed, a role for immunomodulatory therapies targeted towards neutralisation of suppressive cytokines, enhancement of Th1 responses with interferon  $\gamma$ , and transfer of adoptive cellular immunotherapy has been supported.<sup>33,78,79</sup> Addition of recombinant interferon  $\gamma$  to antifungal therapy for cryptococcal meningitis in HIV-infected patients was associated with a trend towards improved clinical and mycological successes.<sup>78</sup> On the one hand, the use of recombinant interferon  $\gamma$  for cryptococcal meningitis will probably not be routine since it may potentially precipitate IRS. On the other hand, the use of recombinant interferon  $\gamma$  might be ideal in combination with antifungal drugs in patients in whom cerebrospinal fluid is difficult to sterilise with standard therapies. Although interferon  $\gamma$  has been successfully used in transplant recipients,<sup>59</sup> another concern with its use is the potential to exacerbate rejection.

## Conclusions

IRS illustrates the complex host–parasite interactions in the evolution of opportunistic mycoses. IRS in fungal infections has been existent for years. However, the use in current medical practice of potent immunomodulators with their ability to rapidly alter immunological status has heightened its relevance. There remain major gaps in our knowledge about virtually all aspects of this entity, but IRS exists and we must deal with it. Characterisation of clinical variables predisposing to IRS, unravelling its immunological basis, and identifying markers that may be diagnostically helpful merit future studies. The treatment of IRS remains empirical, with little precision for agent, dose, or duration. Immunomodulatory therapies are potentially promising and necessary as adjuncts in the management of fungal infections, but

## Search strategy and selection criteria

Data for this Review were identified by searches of Medline for papers on “immune reconstitution syndrome” and “immune reconstitution inflammatory syndrome” in association with “HIV”, “transplant”, “neutropenia”, “cryptococcus”, “histoplasmosis”, “pneumocystis”, “aspergillus”, “fungal infections”, and “mycoses” from January, 1966 to February, 2007. Bibliographies from the articles searched, and articles on these topics in authors’ file collections were also used to identify relevant papers. The search was limited to English language articles or those with an abstract in English language.

balance in the modulation of the immune response that is not too little, not too much, but just right will be essential.

## Conflicts of interest

NS has served on the advisory board of Schering Plough, has received grant support from Schering Plough, Enzon, and Astellas, and is on the speakers bureau for Pfizer. JRP has received support from and is a consultant for Schering Plough, Enzon, Merck, Pfizer, and Astellas.

## Acknowledgments

This work was supported by US National Institutes of Health/National Institute of Allergy and Infectious Diseases grant R01 AI 054719-01 to NS and grant R01 AI 28388 to JP.

## References

- Casadevall A, Pirofski LA. The damage-response framework of microbial pathogenesis. *Nat Rev Microbiol* 2003; **1**: 17–24.
- Roilides E, Dignani MC, Anaissie EJ, Rex JH. The role of immunoreconstitution in the management of refractory opportunistic fungal infections. *Med Mycol* 1998; **36**: 12–25.
- Blanche P, Gombert B, Ginsburg C, et al. HIV combination therapy: immune restitution causing cryptococcal lymphadenitis dramatically improved by anti-inflammatory therapy. *Scand J Infect Dis* 1998; **30**: 615–16.
- DeSimone JA, Pomerantz RJ, Babinchak TJ. Inflammatory reactions in HIV-1-infected persons after initiation of highly active antiretroviral therapy. *Ann Intern Med* 2000; **133**: 447–54.
- French MA, Price P, Stone SF. Immune restoration disease after antiretroviral therapy. *AIDS* 2004; **18**: 1615–27.
- Shelburne SA 3rd, Hamill RJ, Rodriguez-Barradas MC, et al. Immune reconstitution inflammatory syndrome, emergence of a unique syndrome during highly active antiretroviral therapy. *Medicine* 2002; **81**: 213–27.
- Singh N, Lortholary O, Alexander BD, et al. An immune reconstitution syndrome-like illness associated with *Cryptococcus neoformans* infection in organ transplant recipients. *Clin Infect Dis* 2005; **40**: 1756–61.
- Cheng VC, Yuen KY, Wong SS, et al. Immunorestitution disease in patients not infected with HIV. *Eur J Clin Microbiol Infect Dis* 2001; **20**: 402–06.
- Einsiedel L, Gordon DL, Dyer JR. Paradoxical inflammatory reaction during treatment of *Cryptococcus neoformans* var *gattii* meningitis in an HIV seronegative woman. *Clin Infect Dis* 2004; **39**: e78–82.
- Jenny-Avital ER, Abadi M. Immune reconstitution cryptococcosis after initiation of successful highly active antiretroviral therapy. *Clin Infect Dis* 2002; **35**: e128–33.
- Skies DJ. High incidence of immune reconstitution inflammatory syndrome. *Contagion* 2005; **2**: 395–97.
- Shelburne SA, Hamill RJ. Risk of IRIS in patients with opportunistic infections during HAART. *Contagion* 2005; **2**: 389–94.
- Jiang H, Chess L. Regulation of immune responses by T cells. *N Engl J Med* 2006; **354**: 1166–76.
- Parkin J, Cohen B. An overview of the immune system. *Lancet* 2001; **357**: 1777–89.

- 15 Koguchi Y, Kawakami K. Cryptococcal infection and Th1-Th2 cytokine balance. *Int Rev Immunol* 2002; **21**: 423–38.
- 16 Link H. The cytokine storm in multiple sclerosis. *Mult Scler* 1998; **4**: 12–15.
- 17 MacDonald TT. T cell immunity to oral allergens. *Curr Opin Infect Dis* 2006; **10**: 620–27.
- 18 Pakkar NG, Roos MTL, Danner SA, Schellekens PTA. Patterns of T-cell repopulation, virus load reduction, and restoration of T-cell function in HIV-infected persons during therapy with different antiretroviral agents. *J Acquir Immune Defic Syndr Hum Retrovirol* 1997; **16**: 318–26.
- 19 Kelleher AD, Sewell WA, Cooper DA. Effect of protease therapy on cytokine secretion by peripheral blood mononuclear cells (PBMC) from HIV-1 infected subjects. *Clin Exp Immunol* 1999; **115**: 147–52.
- 20 Kostense S, Raaphorst FM, Notermans DW, et al. Diversity of T-cell receptor BV repertoire in HIV-1 infected patients reflects the biphasic CD4+ T-cell repopulation kinetics during highly active antiretroviral therapy. *AIDS* 1998; **12**: F235–40.
- 21 Lortholary O, Fontanet A, Memain N, Martin A, Sitbon K, Dromer F. Incidence and risk factors of immune reconstitution inflammatory syndrome complicating HIV-associated cryptococcosis in France. *AIDS* 2005; **19**: 1043–49.
- 22 D'Elios MM, Josien R, Manghetti M, et al. Predominant Th1 cell infiltration in acute rejection episodes of human kidney grafts. *Kidney Int* 1997; **51**: 1876–84.
- 23 Gras J, Cornet A, Latinne D, Reding R. Evidence that Th1/Th2 immune deviation impacts on early graft acceptance after pediatric liver transplantation: results of immunological monitoring in 40 children. *Am J Transplant* 2004; **4**: 444–45.
- 24 Ferraris JR, Tambutti ML, Cardoni RL, Prigoshin N. Conversion from cyclosporine A to tacrolimus in pediatric kidney transplant recipients with chronic rejection: changes in the immune responses. *Transplantation* 2004; **77**: 532–37.
- 25 Krook H, Wennberg L, Hagberg A, Song Z, Groth CG, Korsgren O. Immunosuppressive drugs in islet xenotransplantation: a tool for gaining further insights in the mechanisms of the rejection process. *Transplantation* 2002; **74**: 1084–89.
- 26 Smith KG, Isabel NM, Catton MG, Leydon JA, Becker GJ, Walker RG. Suppression of the humoral immune response by mycophenolate mofetil. *Nephrol Dial Transplant* 1998; **13**: 160–64.
- 27 Lionakis MS, Kontoyiannis DA. Glucocorticoids and invasive fungal infections. *Lancet* 2003; **362**: 1828–38.
- 28 Hodge S, Hodge G, Flower R, Han P. Methyl-prednisolone upregulates monocyte IL-10 production in stimulated whole blood. *Scand J Immunol* 1999; **49**: 548–53.
- 29 Vecchiarelli A, Retini C, Pietrella D, et al. Downregulation by cryptococcal polysaccharide of tumor necrosis factor alpha and interleukin-1 beta secretion from human monocytes. *Infect Immun* 1995; **63**: 2919–23.
- 30 Vecchiarelli A, Retini C, Monari C, Tascini C, Bistoni F, Kozel TR. Purified capsular polysaccharide of *Cryptococcus neoformans* induces interleukin-10 secretion by human monocytes. *Infect Immun* 1996; **64**: 2846–49.
- 31 Netea MG, Brouwer AE, Hoogendoorn EH, et al. Two patients with cryptococcal meningitis and idiopathic CD4 lymphopenia: defective cytokine production and reversal by recombinant interferon-gamma therapy. *Clin Infect Dis* 2004; **39**: e83–87.
- 32 Lortholary O, Dromer F, Mathoulin-Pélessier S, et al. Immune mediators in cerebrospinal fluid during cryptococcosis are influenced by meningeal involvement and human immunodeficiency virus serostatus. *J Infect Dis* 2001; **183**: 294–302.
- 33 Chaka W, Hyderman R, Gangaidzo I, et al. Cytokine profiles in cerebrospinal fluid of human immunodeficiency virus-infected patients with cryptococcal meningitis: no leukocytosis despite high interleukin-8 levels. *J Infect Dis* 1997; **176**: 1633–36.
- 34 Singh N, Husain S, Limaye AP, et al. Systemic and cerebrospinal fluid cytokine responses in organ transplant recipients with *Cryptococcus neoformans* infection. *Transplant Immunol* 2006; **16**: 69–72.
- 35 Siddiqui AA, Brouwer AE, Wuthiekanun V, Jaffer S, Shattock R. IFN-gamma at the site of infection determines rate of clearance of infection in cryptococcal meningitis. *J Immunol* 2005; **174**: 1746–50.
- 36 Mody CH, Wood CJ, Syme RM, Spurrell JC. The cell wall and membrane of *Cryptococcus neoformans* possess a mitogen for human T lymphocytes. *Infect Immun* 1999; **67**: 936–41.
- 37 Taborda C, Casadevall A. Immunoglobulin M efficacy against *Cryptococcus neoformans*: mechanism, dose dependence, and prozone-like effects in passive protection experiments. *J Immunol* 2001; **166**: 2100–07.
- 38 Tabora C, Rivera J, Zaragoza O, Casadevall A. More is not necessarily better: prozone-like effects in passive immunization with IgG. *J Immunol* 2003; **170**: 3621–30.
- 39 Jalali Z, Ng N, Singh N, Pirofski L. Antibody response to *Cryptococcus neoformans* capsular polysaccharide glucuronoxylomannan in patients with solid organ transplants. *Clin Vaccine Immunol* 2006; **13**: 740–46.
- 40 Breton G, Adle-Biasette H, Therby A, Ramanoelina J, Choudat L. Immune reconstitution inflammatory syndrome in HIV-infected patients with disseminated histoplasmosis. *AIDS* 2006; **20**: 119–21.
- 41 Koval CE, Gigliotti F, Nevins D, Demeter LM. Immune reconstitution syndrome after successful treatment of *Pneumocystis carinii* pneumonia in a man with human immunodeficiency virus type 1 infection. *Clin Infect Dis* 2002; **35**: 491–93.
- 42 Sambatakou H, Denning DW. Invasive pulmonary aspergillosis transformed into fatal mucous impaction by immune reconstitution in an AIDS patient. *Eur J Clin Microbiol Infect Dis* 2005; **24**: 628–33.
- 43 Shelburne SA 3rd, Darcourt J, White C Jr, et al. The role of immune reconstitution inflammatory syndrome in AIDS-related *Cryptococcus neoformans* disease in the era of highly active antiretroviral therapy. *Clin Infect Dis* 2005; **40**: 1045–52.
- 44 Lortholary O, Sitbon K, Dromer F, French Cryptococcus Study Group. Evidence for HIV and *Cryptococcus neoformans* interactions on the pro- and antiinflammatory responses in blood during AIDS-associated cryptococcosis. *Clin Microbiol Infect* 2005; **11**: 296–300.
- 45 Clark DA, Croitoru K. TH1/TH2,3 imbalance due to cytokine-producing NK, gammadelta T and NK-gammadelta T cells in murine pregnancy decidua in success or failure of pregnancy. *Am J Reprod Immunol* 2001; **45**: 257–65.
- 46 Beeson PB. Cryptococcal meningitis of nearly sixteen years' duration. *Arch Intern Med* 1952; **89**: 797–801.
- 47 Todeschini G, Murari C, Bonesi R, et al. Invasive aspergillosis in neutropenic patients: rapid neutrophil recovery is a risk factor for severe pulmonary complications. *Eur J Clin Invest* 1999; **29**: 453–57.
- 48 Caillot D, Couaillier JF, Bernard A, et al. Increasing volume and changing characteristics of invasive pulmonary aspergillosis on sequential thoracic computed tomography scans in patients with neutropenia. *J Clin Oncol* 2001; **19**: 253–59.
- 49 Takuma T, Okada K, Uchida Y, Yamagata A, Sawae Y. Invasive pulmonary aspergillosis resulting in respiratory failure during neutrophil recovery from postchemotherapy neutropenia in three patients with acute leukaemia. *J Intern Med* 2002; **252**: 173–77.
- 50 Denning DW, Marinus A, Cohen J, et al. An EORTC multicentre prospective survey of invasive aspergillosis in haematological patients: diagnosis and therapeutic outcome. EORTC Invasive Fungal Infections Cooperative Group. *J Infect* 1998; **37**: 173–80.
- 51 Price P, Morahan G, Huang D, et al. Polymorphisms in cytokine genes define subpopulations of HIV-1 patients who experienced immune restoration disease. *AIDS* 2002; **16**: 2043–47.
- 52 Price P, Keane NM, Stone SF, Cheong KYM, French MA. MHC haplotypes affect the expression of opportunistic infections in HIV patients. *Hum Immunol* 2001; **62**: 157–64.
- 53 Mitchell DH, Sorrell TC, Allworth AM, et al. Cryptococcal disease of the CNS in immunocompetent hosts: influence of cryptococcal variety on clinical manifestations and outcome. *Clin Infect Dis* 1995; **20**: 611–16.
- 54 Cinti SK, Armstrong WS, Kauffman CA. Recurrence of increased intracranial pressure with antiretroviral therapy in an AIDS patient with cryptococcal meningitis. *Mycoses* 2001; **44**: 497–501.
- 55 Rambeloarisoa J, Batisse D, Thiebaut JB, et al. Intramedullary abscess resulting from disseminated cryptococcosis despite immune restoration in a patient with AIDS. *J Infect* 2002; **44**: 185–88.
- 56 Trevenzoli M, Cattelan AM, Rea F, et al. Mediastinitis due to cryptococcal infection: a new clinical entity in the HAART era. *J Infect* 2002; **45**: 173–79.

- 57 Co DO, Hogan LH, Il-Kim S, Sandor M. T cell contributions to the different phases of granuloma formation. *Immunol Lett* 2004; **92**: 135–42.
- 58 Kawakami K. Regulation by innate immune T lymphocytes in the host defense against pulmonary infection with *Cryptococcus neoformans*. *Jpn J Infect Dis* 2004; **57**: 137–45.
- 59 Summers SA, Dorling A, Boyle JJ, Shaunak S. Cure of disseminated cryptococcal infection in a renal allograft recipient after the addition of gamma-interferon to antifungal therapy. *Am J Transplant* 2005; **5**: 2067–69.
- 60 King MD, Perlino CA, Cinnamon J, Jernigan JA. Paradoxical recurrent meningitis following therapy of cryptococcal meningitis: an immune reconstitution syndrome after initiation of highly active antiretroviral therapy. *Int J STD AIDS* 2002; **13**: 724–26.
- 61 Singh N, Lortholary O, Alexander BD, et al. Allograft loss in renal transplant recipients with *Cryptococcus neoformans* associated immune reconstitution syndrome. *Transplantation* 2005; **80**: 1131–33.
- 62 Breton G, Adle-Biassette H, Therby A, et al. Immune reconstitution inflammatory syndrome in HIV-infected patients with disseminated histoplasmosis. *AIDS* 2006; **20**: 119–21.
- 63 Shelburne SA 3rd, Visnegarwala F, Adams C, Krause KL, Hamill RJ, White AC Jr. Unusual manifestations of disseminated histoplasmosis in patients responding to antiretroviral therapy. *Am J Med* 2005; **118**: 1038–41.
- 64 Wislez M, Bergot E, Antoine M, Parrot A, Carette M-F. Acute respiratory failure following HAART introduction in patients treated for *Pneumocystis carinii* pneumonia. *Am J Respir Crit Care Med* 2001; **164**: 847–51.
- 65 Hughes WT, Feldman S, Aur RJA, Verzosa MS, Hustu HO, Simone JV. Intensity of immunosuppressive therapy and the incidence of *Pneumocystis carinii* pneumonitis. *Cancer* 1975; **36**: 2004–09.
- 66 Cheng VC, Yuen KY, Chan WM, Wong SS, Ma ES, Chan RM. Immunorestitution disease involving the innate and adaptive response. *Clin Infect Dis* 2000; **30**: 882–92.
- 67 Lawn SD, Macallan DC. Hypercalcemia: a manifestation of immune reconstitution complicating tuberculosis in an HIV-infected person. *Clin Infect Dis* 2004; **38**: 154–55.
- 68 Dusso AS, Kamimura S, Gallieni M, et al. gamma-Interferon-induced resistance to 1,25-(OH)<sub>2</sub>D<sub>3</sub> in human monocytes and macrophages: a mechanism for the hypercalcemia of various granulomatoses. *J Clin Endocrinol Metab* 1997; **82**: 2222–32.
- 69 Blumberg HM, Burman WJ, Chaisson RE, et al. American Thoracic Society/Centers for Disease Control and Prevention/Infectious Disease Society of America: treatment of tuberculosis. *Am J Respir Crit Care Med* 2003; **167**: 603–62.
- 70 Razonable RR, Henault M, Lee LN, et al. Secretion of proinflammatory cytokines and chemokines during amphotericin B exposure is mediated by coactivation of toll-like receptors 1 and 2. *Antimicrob Agents Chemother* 2005; **49**: 1617–21.
- 71 Shadkchan Y, Keisari Y, Segal E. Cytokines in mice treated with amphotericin B-intralipid. *Med Mycol* 2004; **42**: 123–28.
- 72 Wheeler RT, Fink GR. A drug-sensitive genetic network masks fungi from the immune system. *PLoS Pathog* 2006; **2**: 328–39.
- 73 Bellocchio S, Gaziano R, Bozza S, et al. Liposomal amphotericin B activates antifungal resistance with reduced toxicity by diverting Toll-like receptor signalling from TLR-2 to TLR-4. *J Antimicrob Chemother* 2005; **55**: 214–22.
- 74 Boelaert JR, Goddeeris KH, Ludo J, Vanopdenbosch LJ, Casselman JW. Relapsing meningitis caused by persistent cryptococcal antigens and immune reconstitution after the initiation of highly active antiretroviral therapy. *AIDS* 2004; **18**: 123–24.
- 75 Briel M, Boscacci R, Furer H, Bucher HC. Adjunctive corticosteroids for *Pneumocystis jirovecii* pneumonia in patients with HIV infection: a meta-analysis of randomised controlled trials. *BMC Infect Dis* 2005; **5**: 101.
- 76 Graybill JR, Sobel J, Saag M, et al. Diagnosis and management of increased intracranial pressures in patients with AIDS. *Clin Infect Dis* 2000; **30**: 47–54.
- 77 Hirsch HH, Kaufmann G, Sendi P, Battegay M. Immune reconstitution in HIV-infected patients. *Clin Infect Dis* 2004; **38**: 1159–66.
- 78 Pappas PG, Bustamante B, Ticona E, et al. Recombinant interferon-gamma 1b as adjunctive therapy for AIDS-related acute cryptococcal meningitis. *J Infect Dis* 2004; **189**: 2185–91.
- 79 Hebart H, Bollinger C, Fisch P, et al. Analysis of T-cell responses to *Aspergillus fumigatus* antigens in healthy individual and patients with hematologic malignancies. *Blood* 2003; **100**: 4521–28.